

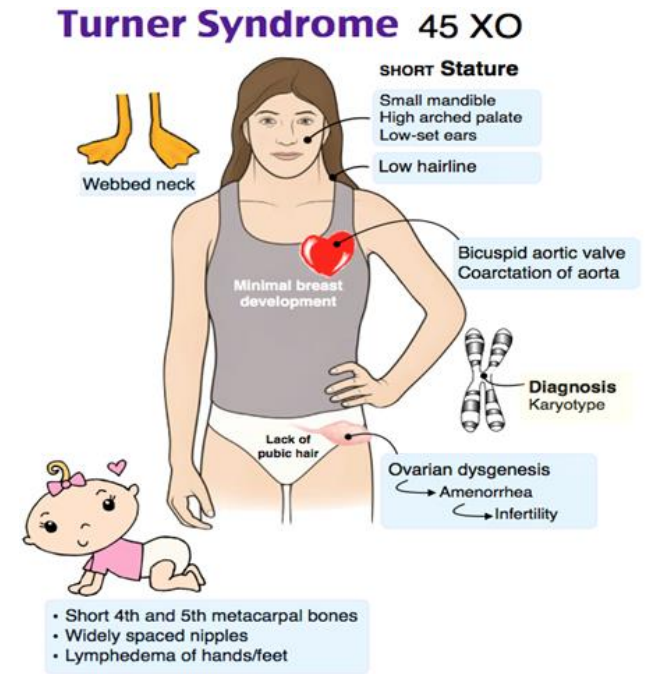


نکاتی پیرامون سندروم ترنر

دکتر رحیم وکیلی  
۲۰۲۱

# WHAT IS TURNER SYNDROME?

Turner syndrome is a chromosomal disorder that affects phenotypic *females* who have one intact X chromosome and complete or partial absence of the second sex chromosome in association with one or more clinical manifestations



Karyotype	%	Description
45,X	40–50	Monosomy X
45,X/46,XX	15–25	
45,X/47,XXX; 45,X/46,XX/47,XXX	3	Mosaicism with 'Triple X'
45,X/46,XY	10–12	Mixed gonadal dysgenesis
46,XX, del(p22.3); 46,X,r(X)/46,XX		Deletion Xp22.3
		Ring X chromosome
46,X i(Xq); 46,X,idic(Xp)	(10%)	Isochromosome Xq; isodicentric Xp
X-autosome translocation, unbalanced	Rare	Various
46,XX,del(q24)		Not TS; premature ovarian failure
46,X,idic(X)(q24)		Not TS; isodicentric Xq24

# Turner syndrome characteristics

Feature	Frequency (%)
Growth failure and reduced adult height	95–100
Failure to thrive during first year of life	50
Endocrinopathies	
Glucose intolerance	15–50
Type 2 diabetes	10
Type 1 diabetes	?
Thyreoiditis and hypothyreosis	15–30, ann. incidence ~3%
Hypertension	50
Android body composition	?
Gastrointestinal and hepatic disorders	
Elevated hepatic enzymes	50–80
Celiac disease	8
Inflammatory bowel disease	2–3
Phenotypic characteristics	
Eyes	
Epicanthus	20
Nearsightedness	20
Strabismus	15
Ptosis	10
Ears	
Infection of middle ear	60
Hearing defects	30
Deformity of external ear	15
Mouth	
Micrognathia (small mandibular bone)	60
High-arched palate	35
Abnormal dental development	?
Neck	
Low posterior hairline	40
Broad short-appearing neck	40
Pterygium colli (webbed neck)	25

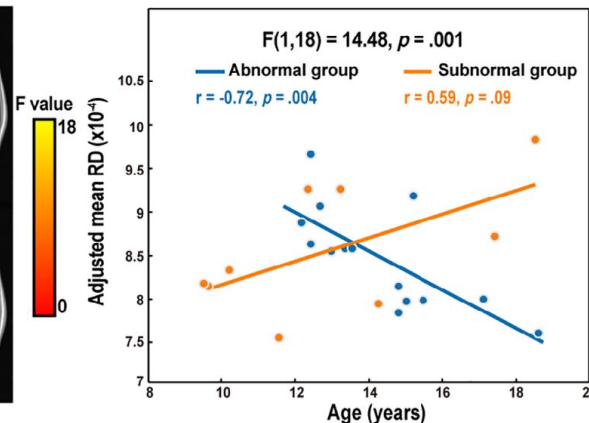
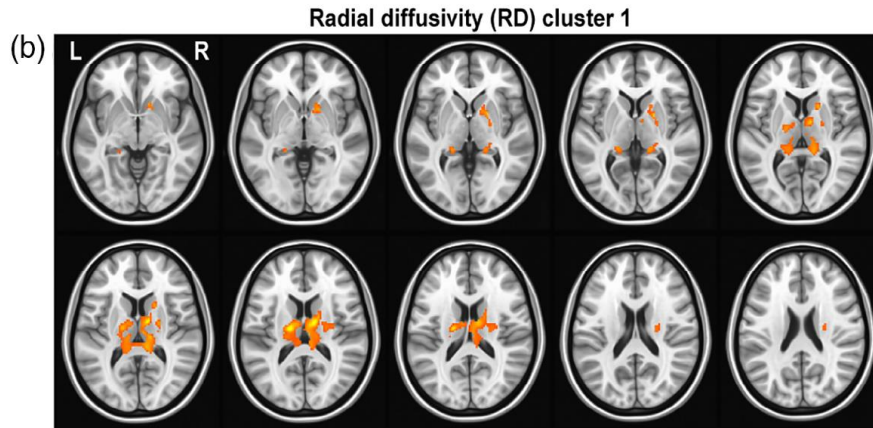
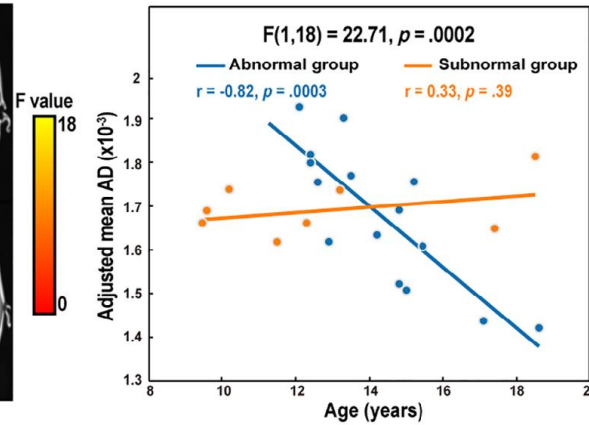
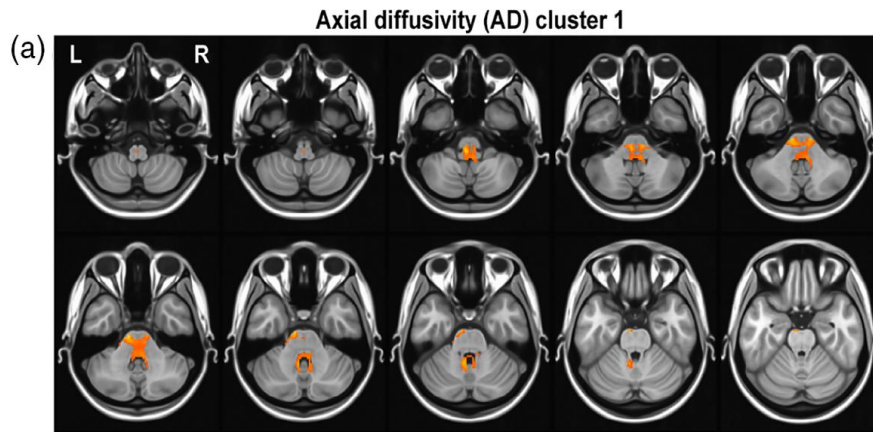
## ***Most typical features:***

- Short stature
- Hypogonadism
- Infertility
- Hypertension
- Hypothyroidism
- Middle ear infections
- Hearing disability



# Estradiol and Brain function

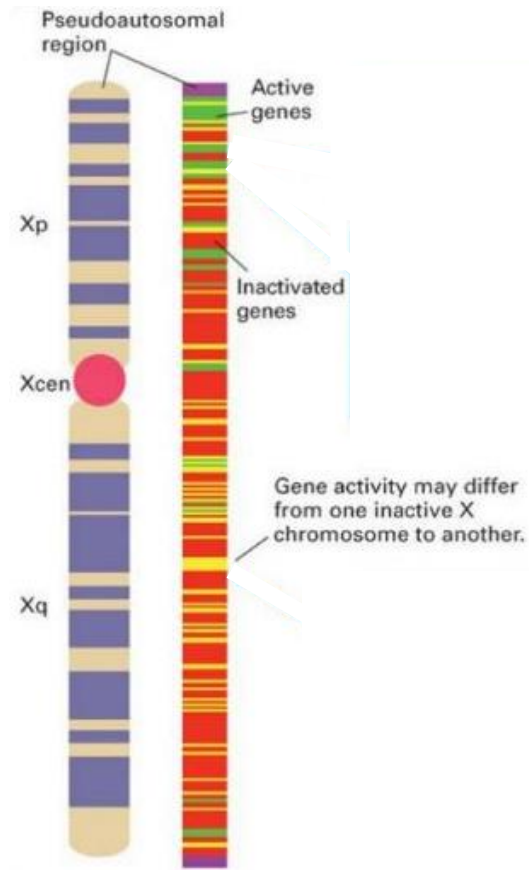
	Abnormal group (n = 14)	Subnormal group (n = 9)
Age	14.30 ± 1.92	12.93 ± 3.27
FSH level (mIU/mL)	108.6 ± 35.87 (14)	6.76 ± 5.23 (9)
E2 level (pmol/mL)	17.5 ± 15.25 (13)	64.73 ± 74.31(9)



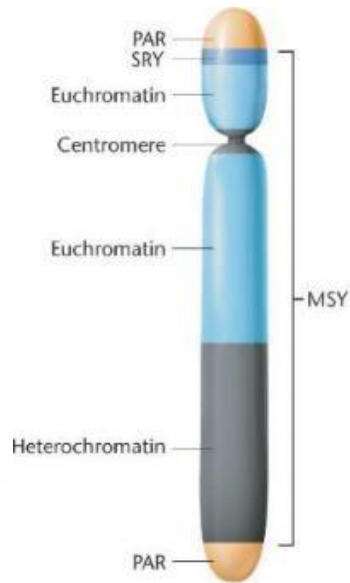
This study and other studies suggest that age-appropriate exposure to estradiol is important for normal brain development

# Genetics of Turner syndrome

X chromosome

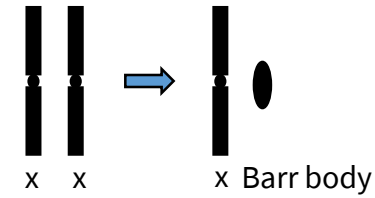


Y chromosome

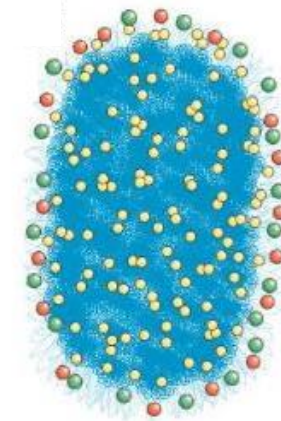







Key: PAR: Pseudoautosomal region  
SRY: Sex-determining region of the Y  
MSY: Male-specific region of the Y

Dose compensation & X chromosome inactivation



Barr body



-  Barr body heterochromatin (primarily silenced non-coding DNA)
-  Non-Barr body chromatin (primarily genic DNA)
-  Xist RNA
-  Genes escaping X inactivation
-  Genes subject to X inactivation

# Turner syndrome

## Genetics of syndromes

X

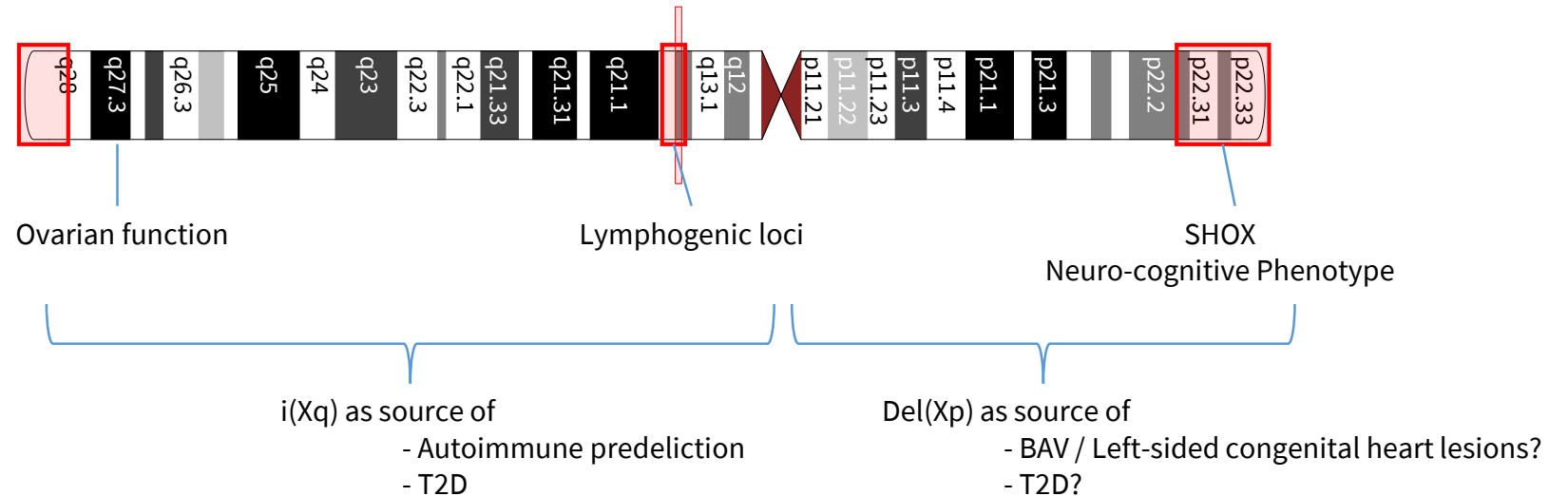
What happens with loss of X?

X X

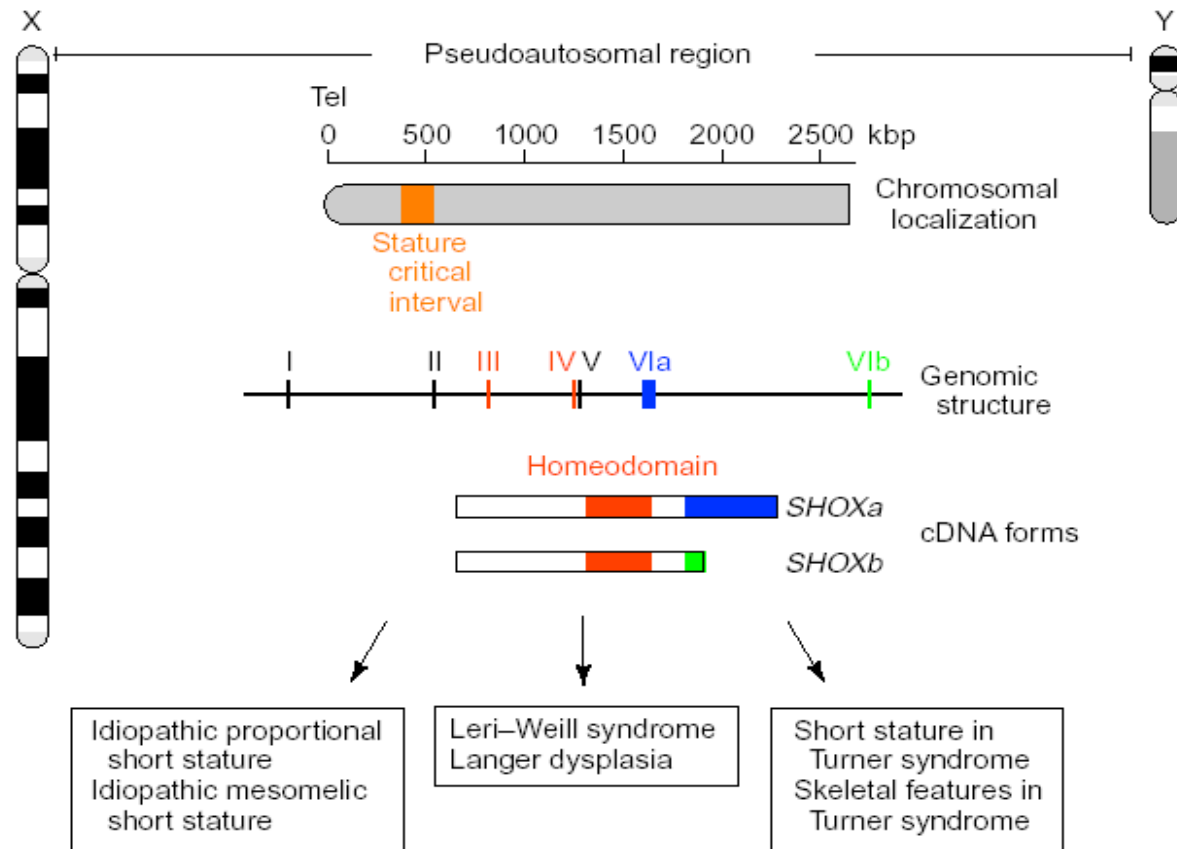
- 65 % is shut down
- 20 % with variable expression
- 15 % “escapes” X-inactivation

X Y

→ Pseudoautosomal region Y and X



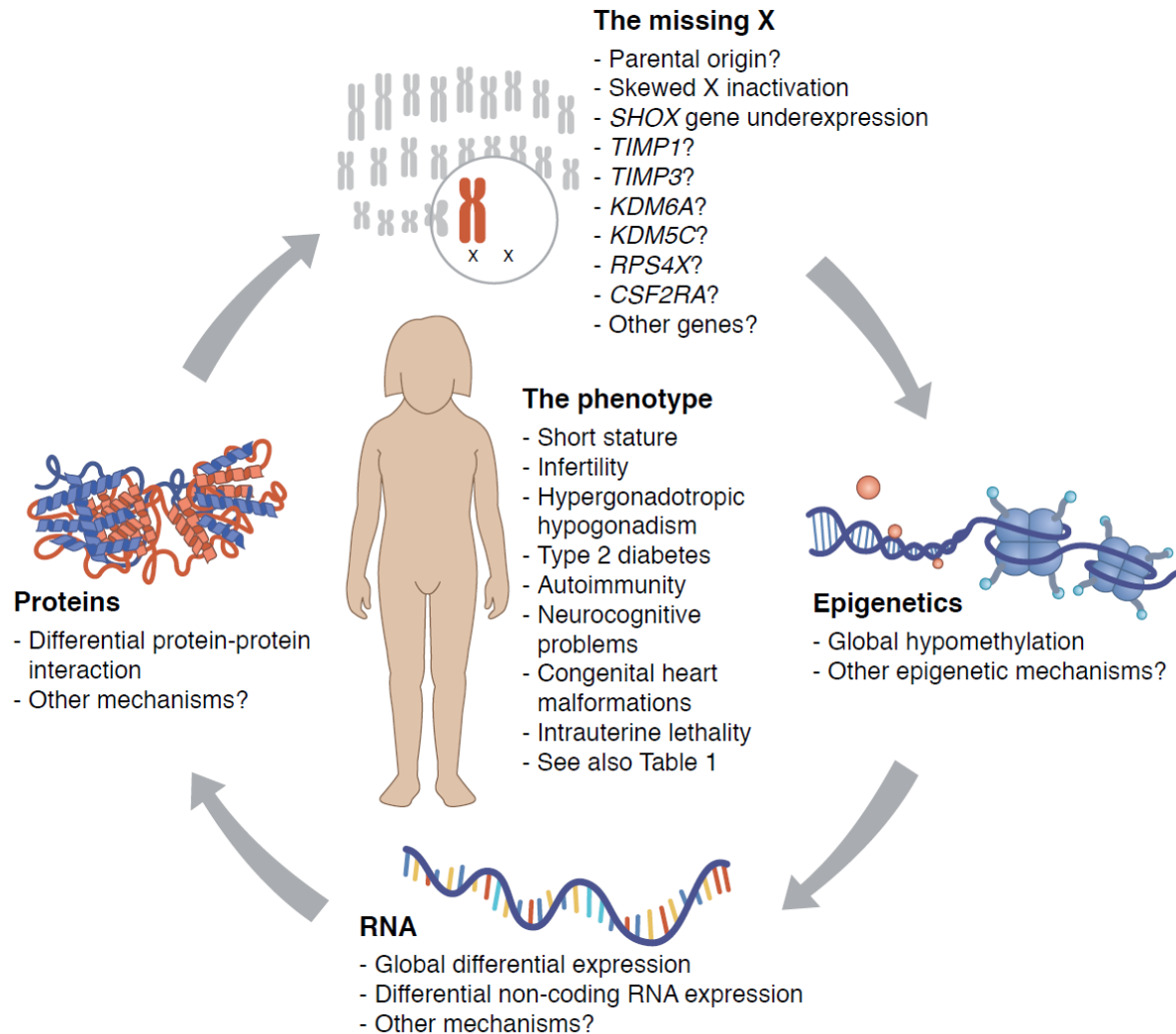
# SHOX – part of an explanation!



## Consequences:

- short 4th metacarpal
- cubitus valgus
- Madelung deformity
- mesomelic growth
- high arched palate
- micrognathia
- sensorineural deafness
- dysproportionality of skeletal size

# Turner syndrome pathophysiology



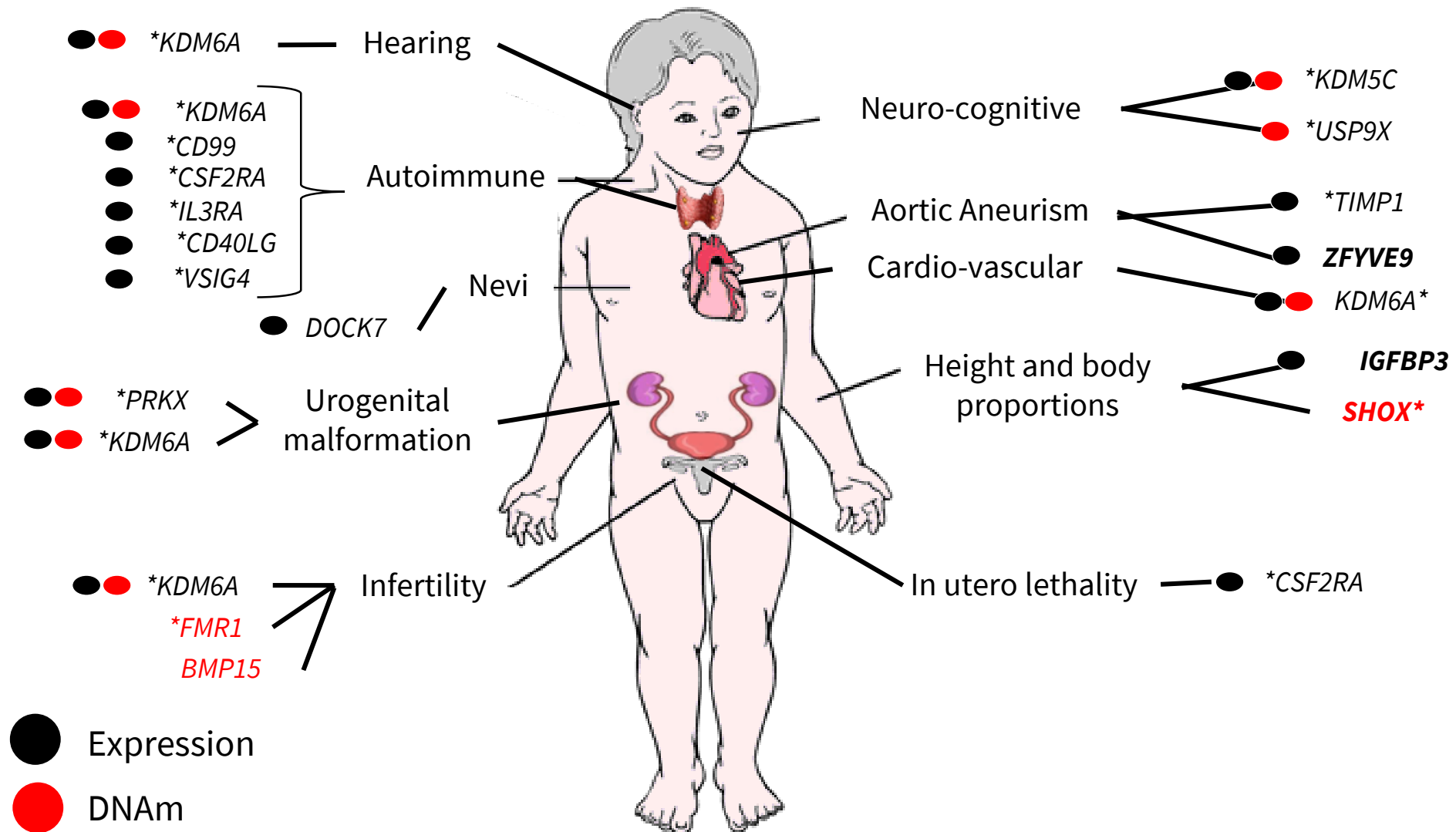
It is clear that the missing X chromosome is the cause for the problems related to Turner syndrome

The *SHOX* gene is responsible for part of the growth failure and some skeletal abnormalities

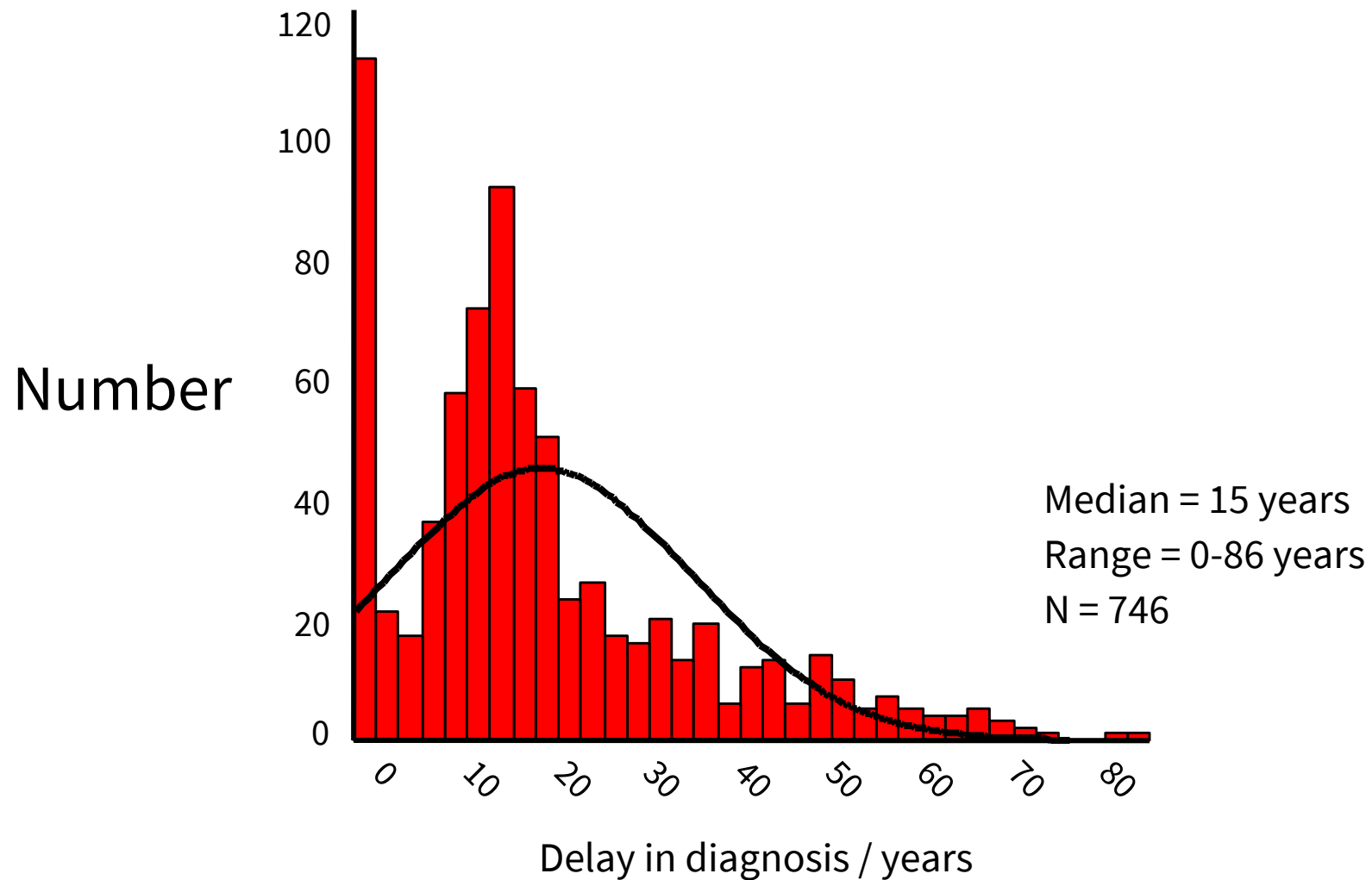
But we don't know which genes are responsible for all the other traits

This is hugely interesting and much current research is focussing on this





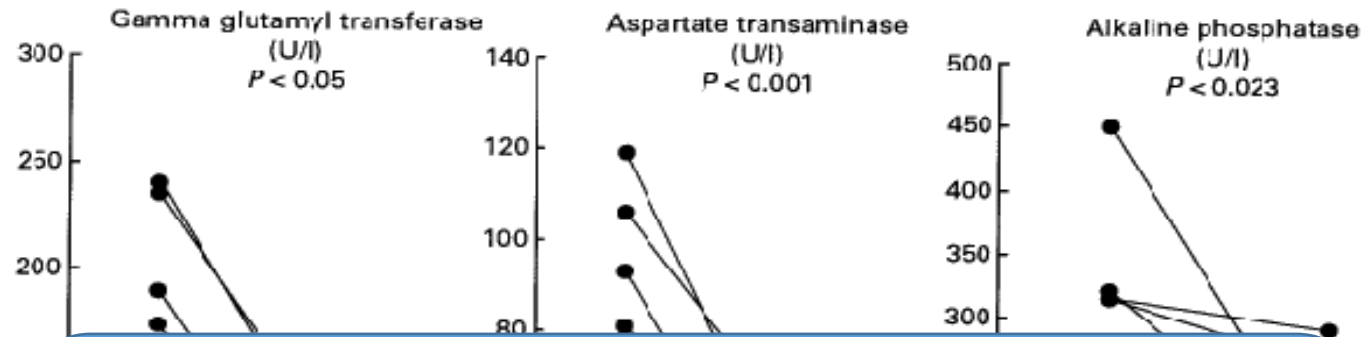
# Time of diagnosis of Turner syndrome?



# Autoimmunity – Turner syndrome

Autoimmune disease	Observed	Expected	SIR (95% CI)
Male-predominant			
Reactive arthritis	1	0.1	22.1 (1.3–97.2)
Dupuytren's contracture	4	0.6	7.0 (2.2–16.2)
Ankylosing spondylitis	1	0.3	3.7 (0.2–16.4)
Amyotrophic lateral sclerosis	1	0.1	22.2 (1.3–97.7)
Type 1 diabetes mellitus	18	4.4	4.1 (2.5–6.3)
Male-predominant autoimmune diseases overall*	23	5.8	3.9 (2.5–5.8)
Female-predominant			
Sarcoidosis	3	1.0	3.1 (0.8–7.9)
Psoriasis	3	1.9	1.6 (0.4–4.2)
Ulcerative colitis	8	3.2	2.5 (1.2–4.7)
Rheumatic fever	1	0.2	6.2 (0.4–27.2)
Polyarteritis nodosa	1	0.1	14.0 (0.8–61.6)
Idiopathic thrombocytopenic purpura	2	0.3	5.9 (1.0–18.4)
Crohn's disease	3	2.0	1.5 (0.4–3.9)
Celiac disease	1	0.4	2.7 (0.2–11.7)
Juvenile rheumatoid arthritis	2	0.5	4.4 (0.7–13.6)
Multiple sclerosis	2	1.8	1.2 (0.2–3.5)
Temporal arteritis/polymyalgia rheumatica	1	0.9	1.2 (0.1–5.1)
Rheumatoid arthritis	3	3.2	0.9 (0.2–2.4)
Graves' disease	5	4.4	1.2 (0.4–2.5)
Sjögren's syndrome	1	0.5	2.2 (0.1–9.9)
Hashimoto thyroiditis	8	0.6	14.6 (6.7–27.1)
Female-predominant autoimmune diseases overall*	37	21.4	1.7 (1.2–2.4)
All autoimmune diseases*	55	26.6	2.1 (1.6–2.7)

# Liver parameters



For liver function It does not seem to be a "window of opportunity" – at least when participants are below 50 years of age

20 women with Turner syndrome, with and without HRT (3 month). HRT reduces liver enzymes.

# Effects of HRT

## Central nervous system

- Improved verbal and nonverbal memory
- Improved processing speed and motor function
- Improved self-esteem

## Liver metabolism

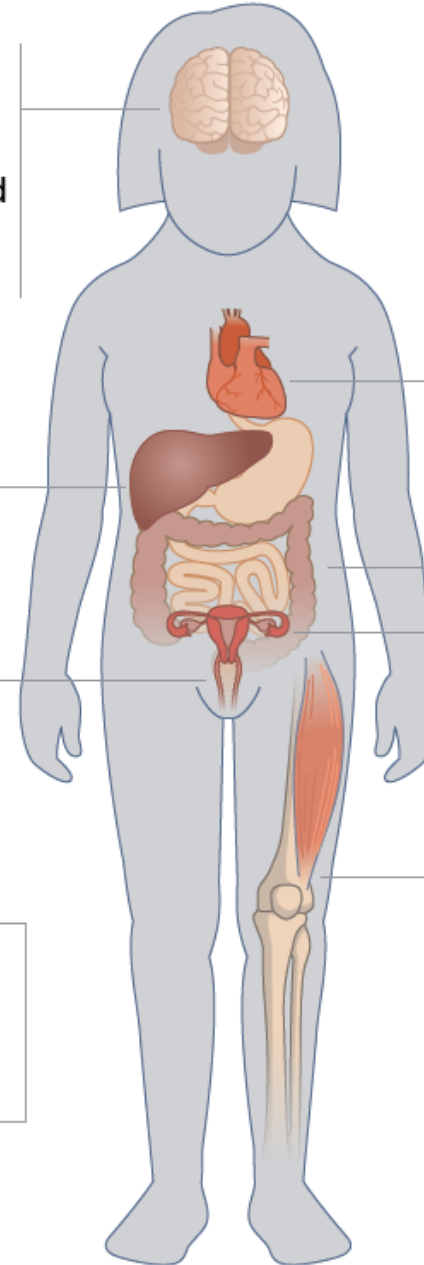
- Normalized liver enzymes

## Sexual function

- Normal sexual desire
- Normal debut of sexual activity

## Cancer risk

- No increased risk of breast cancer



## Longevity

- Positive impact of HRT?

## Cardiovascular system

- Lower blood pressure
- Improved lipide profile
- Normalized coagulation system

## Weight and metabolic changes

- Decreased visceral adiposity
- Increased muscle mass

## Urogenital system

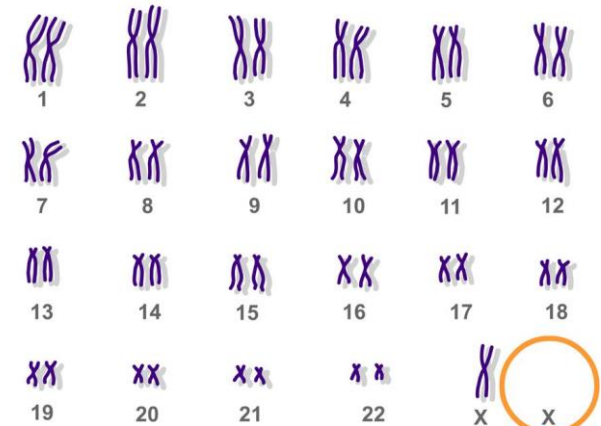
- Normal uterine length and volume
- Vaginal moistness

## Musculoskeletal system

- Increased muscle mass
- Normal bone mineral density

# PRECOCIOUS PUBERTY IN TURNER SYNDROME

The patient was diagnosed with TS at the age of 4 years, upon a diagnostic work-up for dysmorphic features. Chromosome analysis revealed a mosaic karyotype (45X0/47XXX). She presented with normal height and normal growth velocity so that Growth Hormone (GH) therapy was not started. She was referred to our Department at the age of 7 years and 10 months, because of vaginal bleeding. A physical examination revealed a Tanner stage III for breast and Tanner stage III for pubic hair development. Height and weight were within the normal range for age



# PRECOCIOUS PUBERTY IN TURNER SYNDROME

Absent pubertal development and primary amenorrhea occurs in most individuals with TS, due to accelerated loss of oocytes in the 45,X ovary, leaving few follicles in a fibrous stroma by birth. Approximately one third of girls with TS undergo spontaneous puberty, but only half of those complete puberty with menarche. Spontaneous pregnancies are rare (2-5%) [4]. A few rare cases of precocious puberty have been described, mainly in girls with mosaic TS (45X0/46XX or X structural abnormalities).

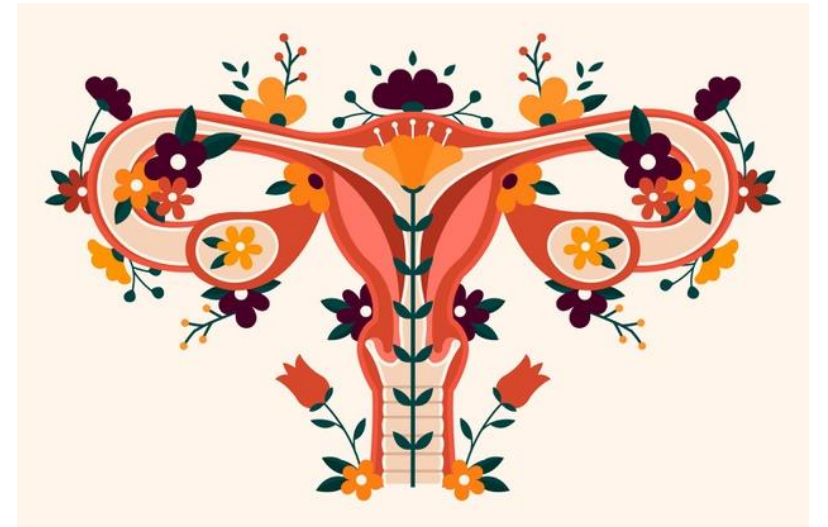We report on the first case of precocious puberty in a 45X0/47XXX mosaic TS.

Nicola Improda, Ital J Pediatr. 2012; 38: 54.

# TURNER SYNDROME

Preservation of fertility may be feasible by cryopreservation of ovarian tissue before follicles have totally vanished.

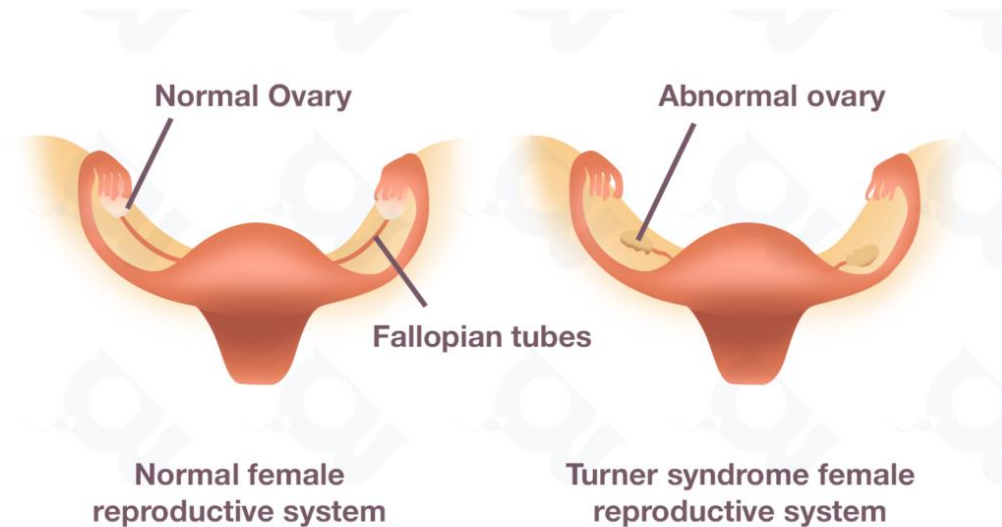
AMH assay, often considered a marker of ovarian reserve, is detectable in a fifth of Turner girls . essentially those with a mosaic 46,XX cell line, indicating that follicles are still present and cryopreservation is still a viable option.





# PROGRESS IN FERTILITY PRESERVATION STRATEGIES IN TURNER SYNDROME

The risks of premature ovarian failure and infertility in TS are extremely high, as the ovarian reserve in girls with TS will be already exhausted before adulthood. In order to maximize the benefits of fertility preservation, it is recommended that all women with TS should be diagnosed as early as possible, evaluated for ovarian reserve, and be offered options for fertility preservation in case of residual ovarian function.



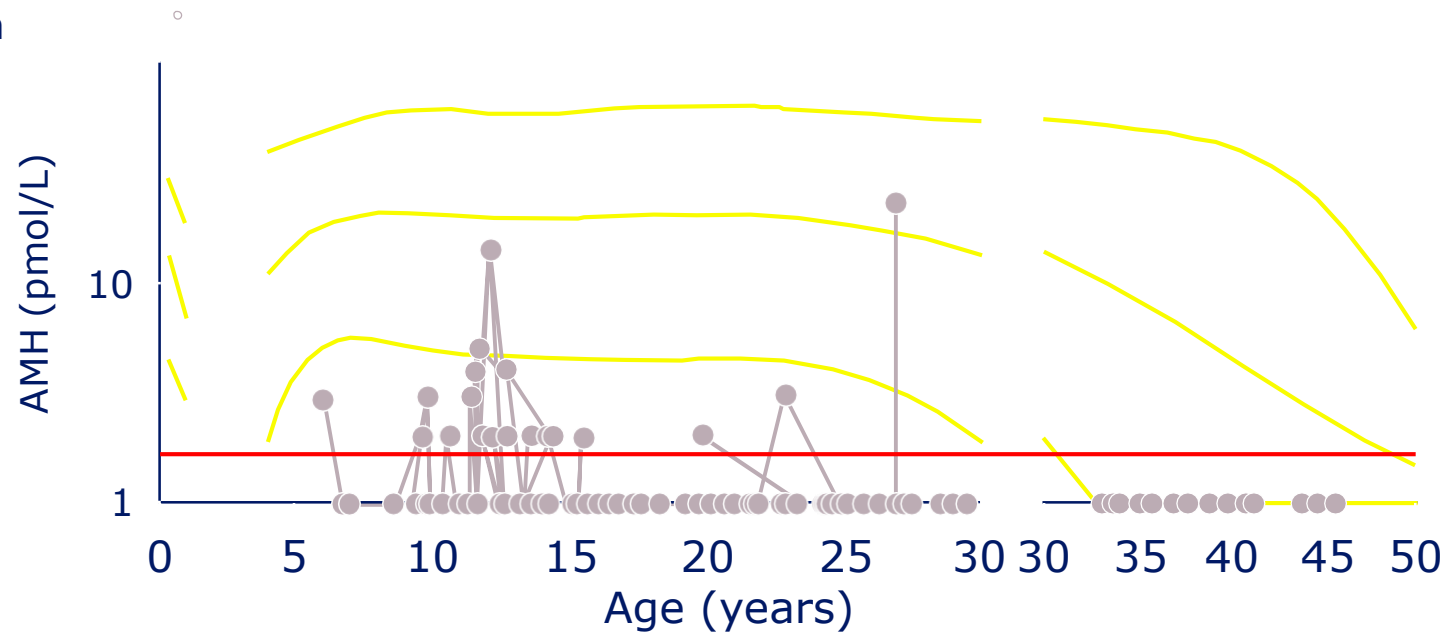
Cryopreservation of oocytes and embryos are two well-established methods of fertility preservation available for women with TS. Cryopreservation of ovarian tissue is still in experimental stage, but appears to be a promising technique, especially if accompanied with the ovarian activation in vitro technique. For those women with TS who have lost their ovarian reserve, oocyte or embryo donation and adoption can be a way to fulfill their childcare aspirations. The risks of spontaneous abortion, fetal abnormalities, maternal complications, and mortality in women with TS are much higher than those in women with normal karyotypes. Patients with TS with pregnancy contraindications can use their own or donors' oocytes or embryos for gestational surrogacy.



# Anti-Müllerian (AMH) as predictor of ovarian failure in TS

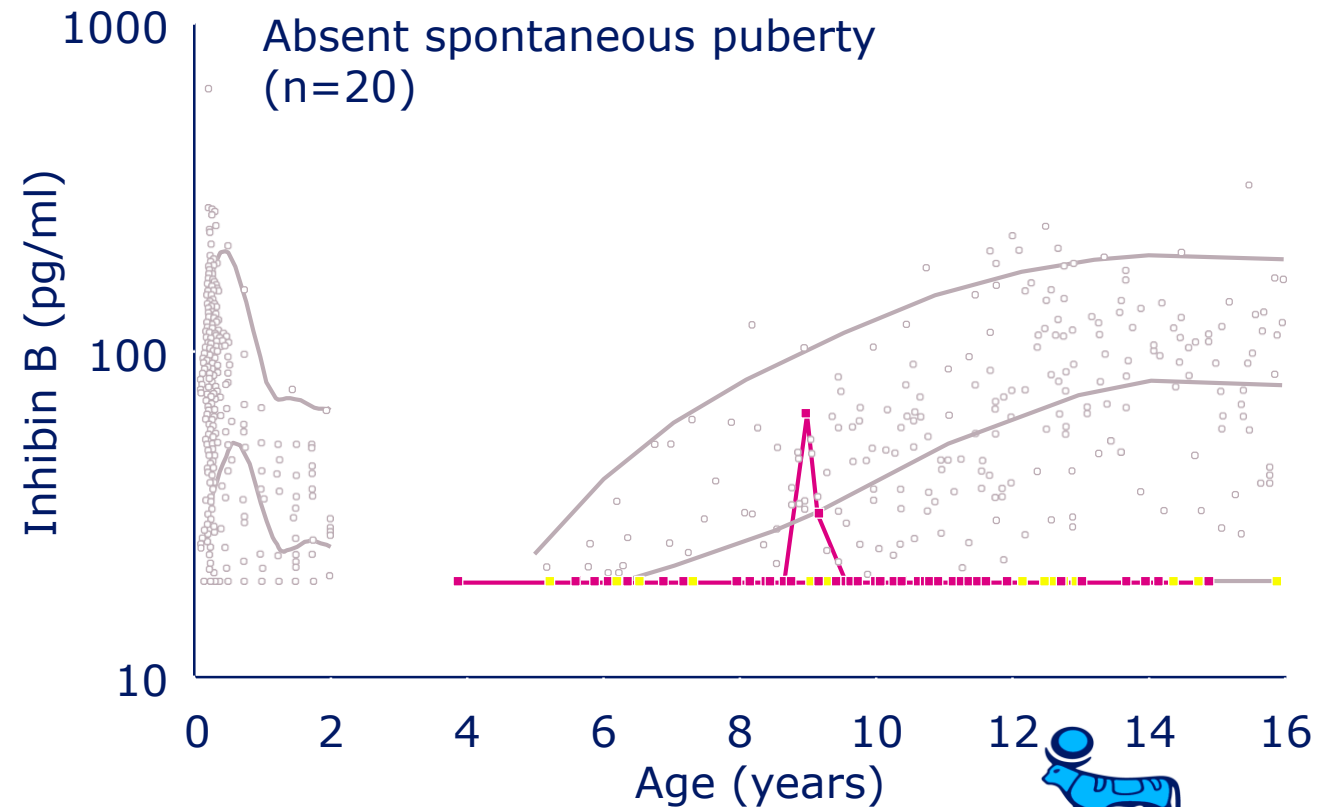
- Granulosa cell product from ovarian follicles
- AMH associated with ovarian status (N=120 TS)
- AMH <4pmol/L ( $\leq 2$  SD) predicted ovarian failure
- AMH correlated with remaining ovarian function between 12–25 years

No ovarian function  
100



# Serum inhibin B as predictor of ovarian failure in TS

- 70 TS patients
- 2,406 controls
  
- Undetectable inhibin B may predict absence of spontaneous puberty, although specificity of test low



# Markers of gonadal function in TS: summary

- FSH: elevated in early childhood, declines mid-childhood, elevated at time for puberty
- LH: similar to FSH but less markedly abnormal
- Inhibin: generally undetectable
- AMH: undetectable or very low; correlates with ovarian “reserve”
- Oestradiol: low at time for puberty
- **No single lab is sensitive and specific**
- **LH, FSH, AMH, inhibin B in combination are best**
- **Value of pelvic ultrasounds is not clear**

# What can be done about oocyte preservation and pregnancy in TS?

- Endogenous oocytes
  - IVF stimulation in women with TS (35 cycles/22 women): pregnancy rate 8.6%, live birth rate 5.7%
  - Possibility of using cryopreserved ovarian tissue/immature oocytes
- is currently under intensive research investigation (what age?)
- Oocyte donation and IVF
  - Pregnancy rate is 40% per treatment cycle
  - But, only 50% result in live birth, secondary to uterine hypoplasia or ischemia
- Increased risk for maternal cardiovascular complications with pregnancy
  - Risk of death [aortic dissection]



# GONADAL DYSGENESIS IN TURNER SYNDROME WITH Y-CHROMOSOME MOSAICISM

different tissues in the same TS individual may exhibit different ratios of mosaicism, and the gonadal determination and differentiation of mosaic TS are primarily dependent on the predominant cell line in the gonads. The mosaicism of Y chromosome sequences in TS is related to the potential for gonadoblastoma. Therefore, in TS patients with virilization, it is necessary to test at least two to three tissues to search for cryptic Y material, such as peripheral blood, buccal mucosa cells, skin fibroblasts, and especially gonadal tissue. However, conventional karyotype analysis is not sufficient. PCR or FISH analysis should be used to enhance the efficiency of screening for Y-chromosomal material in TS patients.

THANKS FOR YOUR ATTENTION

