

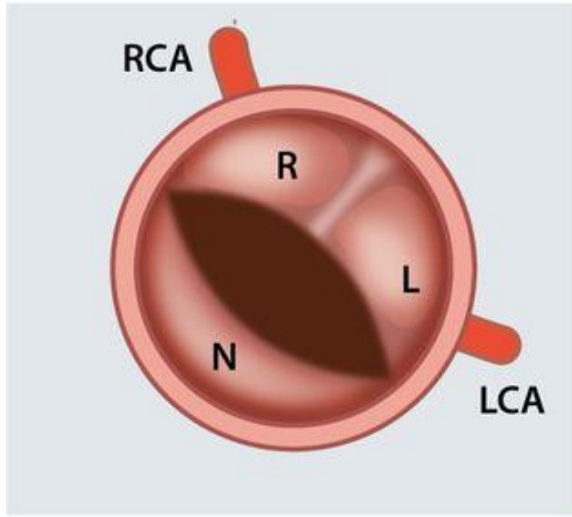
# Turner syndrome: Congenital heart disease, mechanisms and management



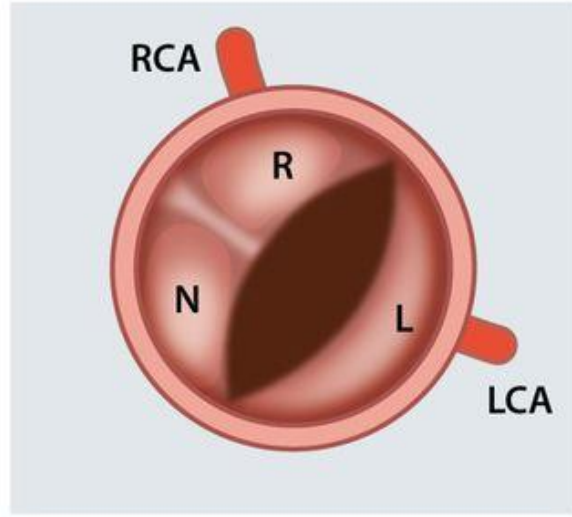
Dr GHandi - associate pediatric cardiology -  
arak medical university /2021

- Cardiovascular morbidity is profound in Turner syndrome and congenital heart disease contributes to this effect.
- In prepubertal girls with Turner syndrome, aortic stiffness is already increased and the most common congenital malformation is a **bicuspid aortic valve**, which is found in **~25%** of individuals with Turner syndrome.

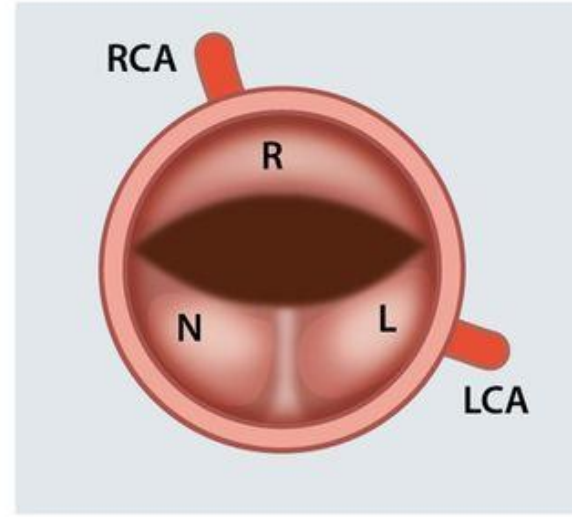
RL BAV with raphe



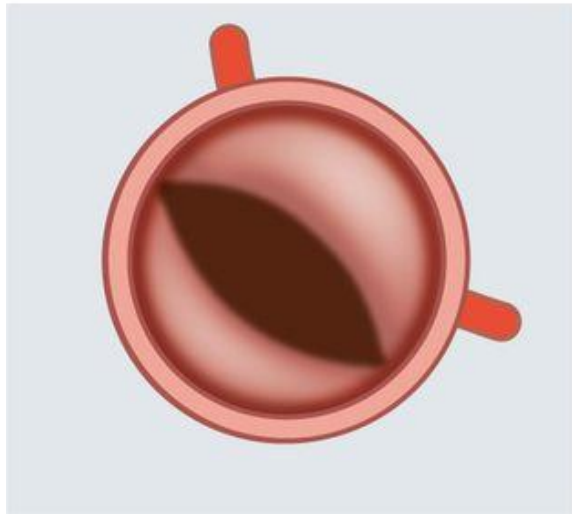
RN BAV with raphe



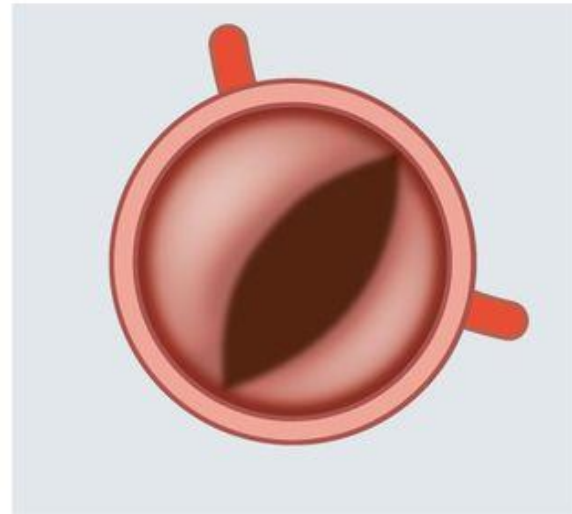
LN BAV with raphe



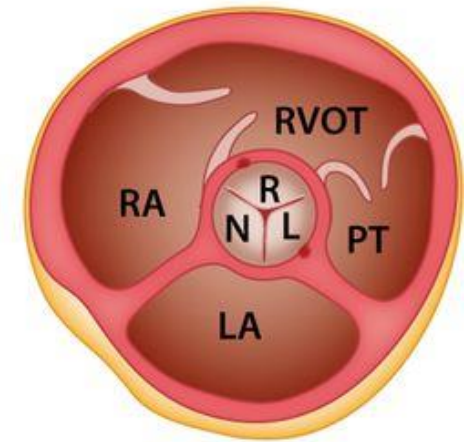
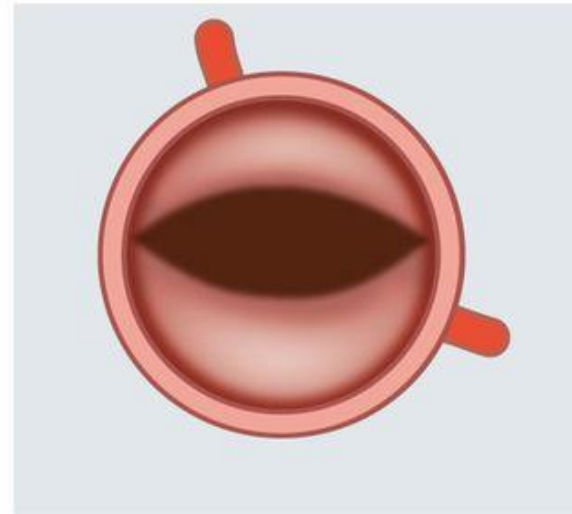
RL BAV without raphe



RN BAV without raphe

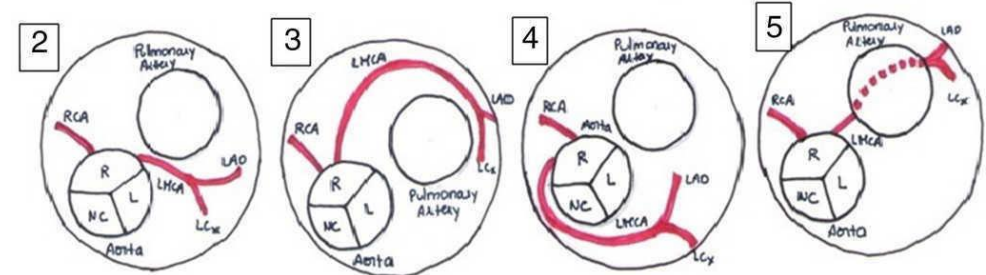
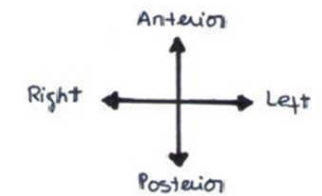
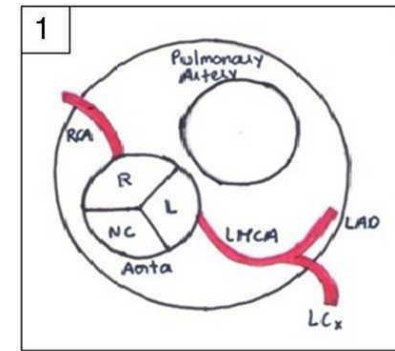
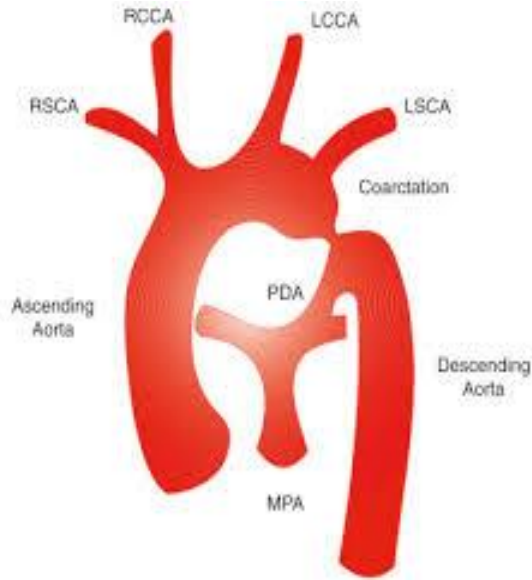
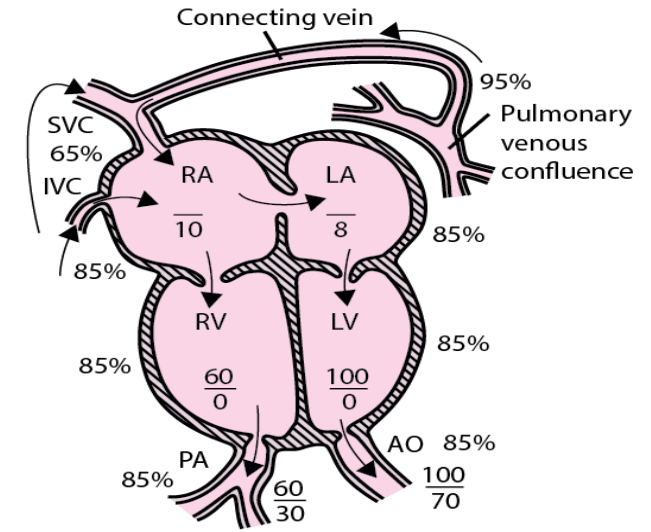
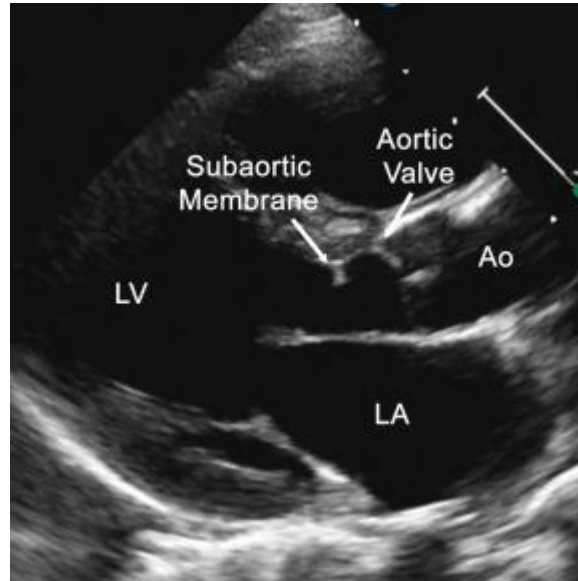


LN BAV without raphe

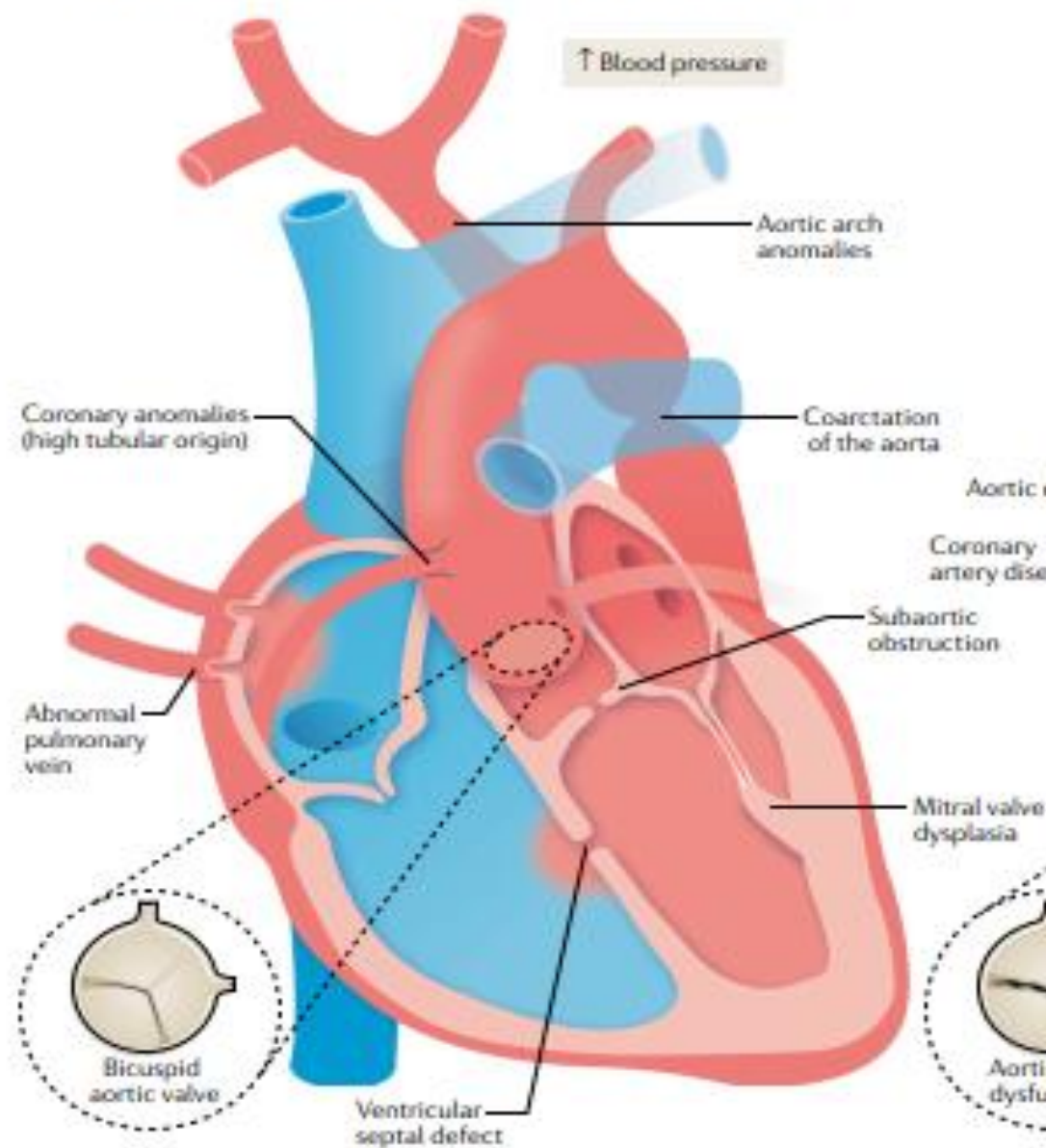


- The increased prevalence of bicuspid aortic valve in Turner syndrome links with **karyotype** and is seen more frequently in women with the **45,X karyotype**.
- As mentioned previously, the association between Turner syndrome and **aortic bicuspid valve** is probably linked with numerous complex mechanisms, one of which is seemingly the influence of **TIMP1 and TIMP3**.

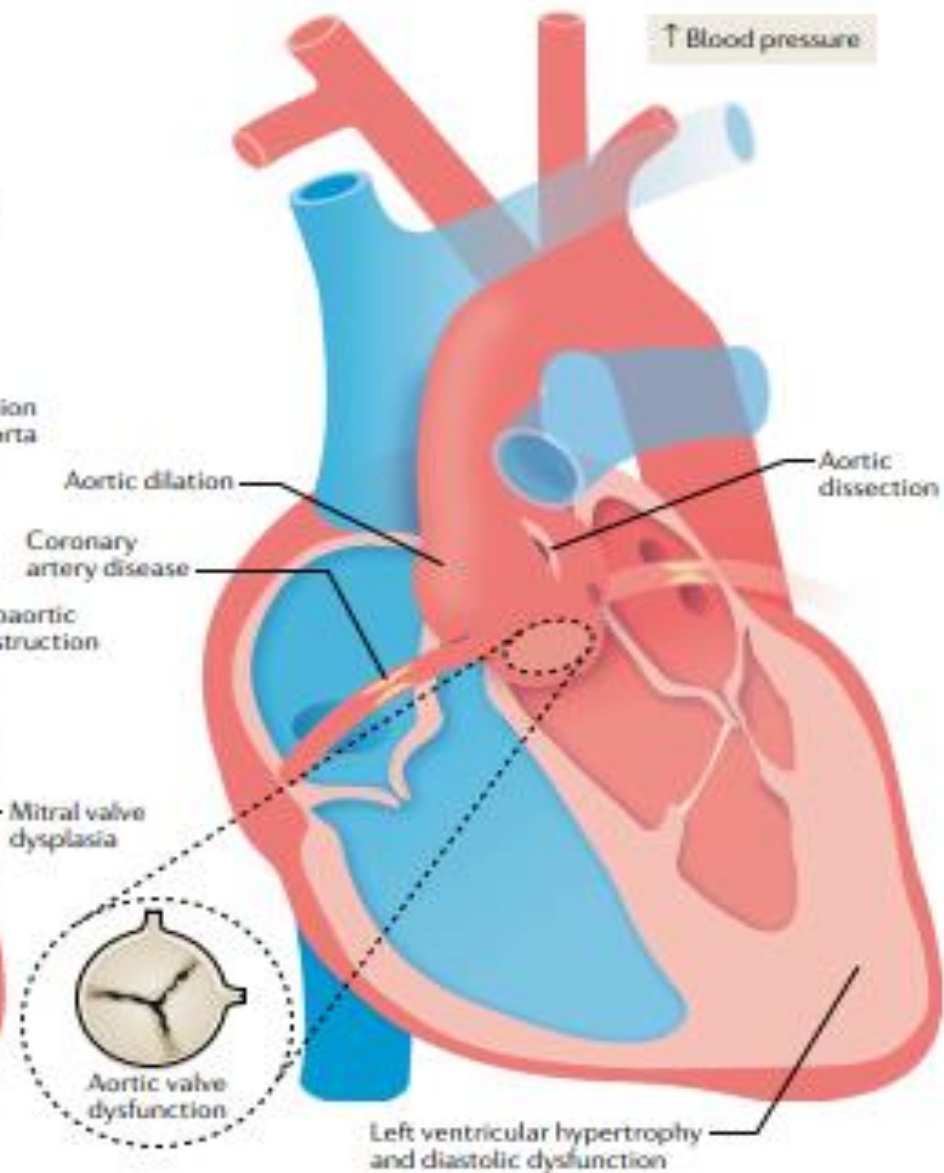
- Other presentations of congenital heart disease are also common in Turner syndrome and can be present in isolation or found in combination with several congenital heart defects in the same individual .
- **Other left-sided congenital lesions**, such as coarctation of the aorta, abnormal pulmonary vein drainage, subaortic obstruction, mitral valve dysplasia and coronary anomalies, commonly occur.



**a Congenital anomalies associated with Turner syndrome**



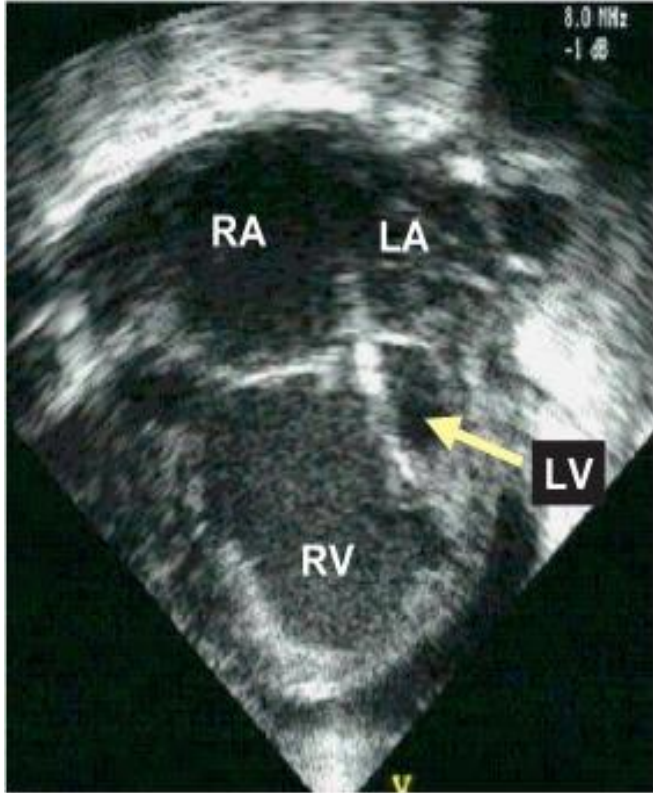
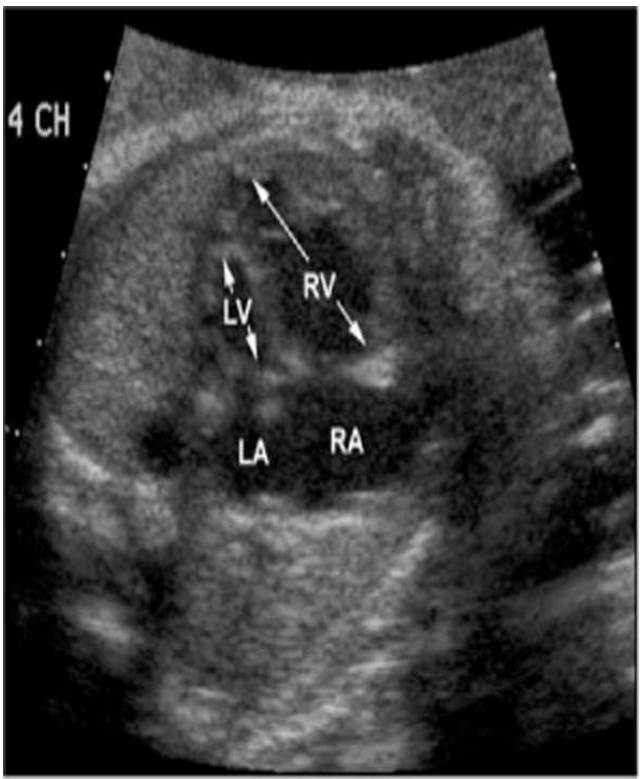
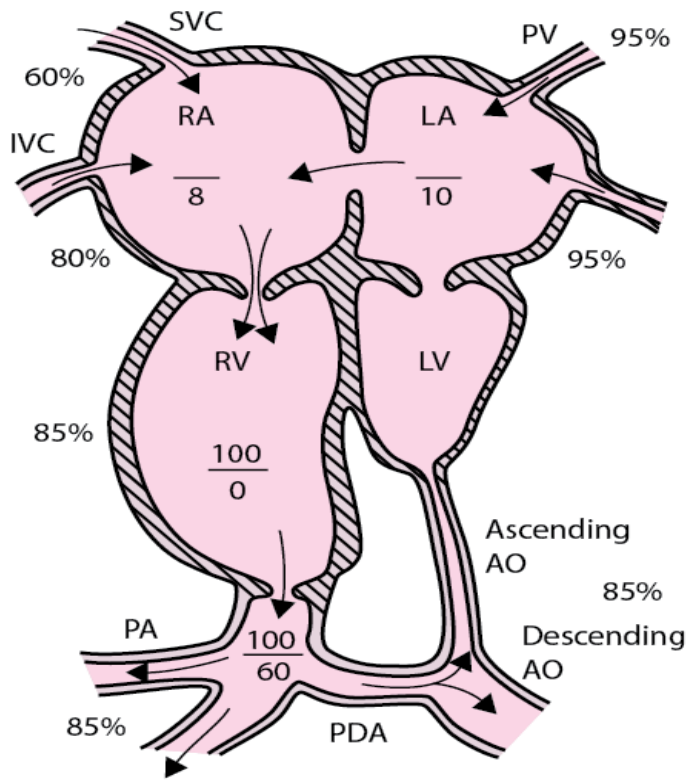
**b Acquired heart diseases in adult Turner syndrome**



- The **true prevalence of** congenital heart disease in Turner syndrome is difficult to report, since certain anomalies can remain asymptomatic into adulthood(for example, abnormal pulmonary veins and coronary anomalies).
- As such, it is important for any physician to perform a thorough clinical exam upon **initial diagnosis** or **later on during adult life** and apply the appropriate imaging techniques to detect any given problem considerable data support this statement.



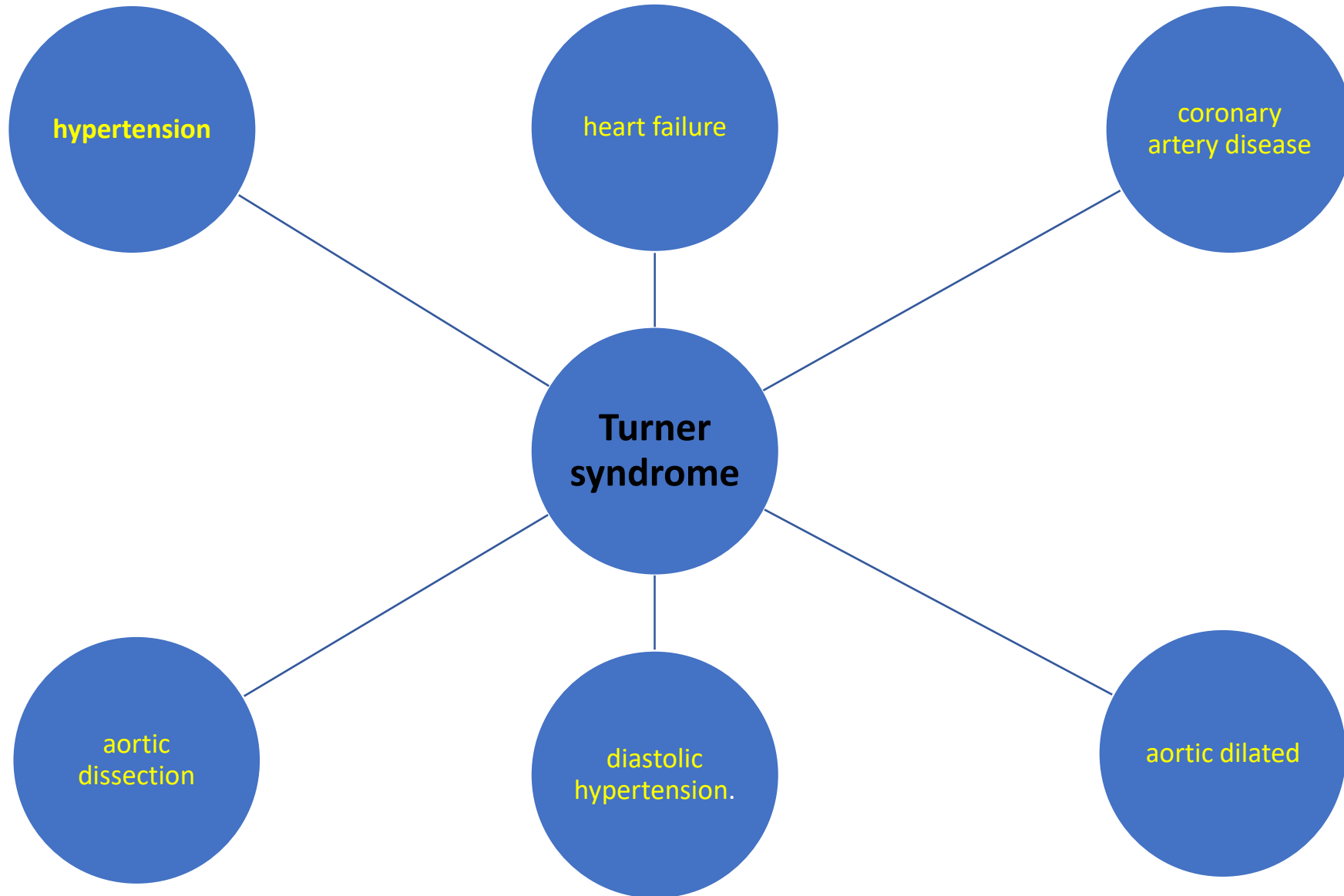
- A **rare** finding in the general population, however not uncommon in fetuses with Turner syndrome is hypoplastic left heart syndrome (**HLHS**).
- which is a high-risk syndrome with increased neonatal mortality.
- These disturbing figures are important consideration for **prenatal counselling**.



# Summery

- bicuspid aortic valve
- aortic stiffness
- coarctation of the aorta
- abnormal pulmonary vein drainage
- subaortic obstruction
- mitral valve dysplasia
- coronary anomalies
- HLHS

# Adult cardiovascular disease



- Adult women with Turner syndrome are at increased risk of *hypertension , coronary artery disease, heart failure and aortic dissection*, indeed, the risk of **aortic dissection**, which can be rapidly fatal, is **increased 100-fold** compared with the general population .

- Of note, the risk of **spontaneous dissection** is increased when the **aorta is dilated** ; however, dissections can occur even with **normal aortic diameters** and at younger age among individuals with Turner syndrome.

- **Aortic dilatation** in Turner syndrome is common and is associated with congenital heart defects, such as **aortic arch abnormalities**, a **bicuspid aortic valve** and **coarctation of the aorta**, as well as **diastolic hypertension**.



- Routine follow-up of **aortic size** by **echocardiography** or **MRI** depends on the burden of risk factors; therefore, women with Turner syndrome and a normal aortic phenotype may only need a check-up **every 5 years**, whereas women with aortic dilatation, coarctation and hypertension may need **at least annual check-ups**.

- Prophylactic surgery is advised at an absolute ascending aortic diameter  $>4$  cm or an indexed size  $\geq 2.5$  cm/m<sup>2</sup>, yet both measures may need to be assessed since, in very small individuals, an absolute diameter may underestimate a dangerous dilation of the aorta.

- Adult women with Turner syndrome also have a high prevalence of **ischemic heart disease** and **stroke**.
- Therefore, cardiovascular morbidity and mortality in adult life is statistically significantly higher in women with Turner syndrome compared with the background Population.

- The **lean** and **normotensive** woman with Turner syndrome that is **well controlled with hormonal replacement** therapy might never develop ischemic heart disease, whereas the **hypertensive** patient with Turner syndrome with **insufficient estrogen** substitution throughout life, **obesity** and **T2DM** is at very high risk of developing **stroke** or a **myocardial infarction**.

- It is important to pick up early symptoms indicative of angina and to be aware that these symptoms may develop in **early adulthood**.

- The increased risk of **stroke** does not seem associated with a general increased risk of **thrombosis** in women with Turner syndrome and could be explained by the plethora of comorbidities that evolve over a lifetime, including **diabetes mellitus, hypertension and dyslipidemia**, among others.

- However, *sporadic reports* do exist about increased risk of **deep venous thrombosis** in women with Turner syndrome, but whether these findings relate to a general problem in the coagulation system is far from settled.

- As in the general population, a proportion of women with Turner syndrome do have abnormal coagulation but Turner syndrome is not associated with a generally increased risk of thrombosis and clinicians **should not be concerned** about estrogen treatment and thrombosis risk.



- **Hypertension** is an important predisposing risk factor for the development of *aortic dissection and stroke*.
- Blood pressure is increased in individuals with Turner syndrome already in childhood and early adolescence and, in adulthood, **hypertension occurs in up to 50%.**

- **Both systolic and diastolic blood pressure** increase statistically significantly early in life in women with Turner syndrome with slight positive impact of treatment with **estradiol and estradiol deficiency** is associated with increased blood pressure.

- The nature of hypertension in individuals with Turner syndrome remains **unexplained**; furthermore, no consistent signs of secondary hypertension have been found.

- The pathophysiology of hypertension could be associated with a combination of influences, such as **dysregulation of the sympathetic nervous system** and altered sympathovagal tone, **abnormal wiring of the parasympathetic and sympathetic nervous system** with increased **resting noradrenaline levels**, or **coarctation of the aorta**— factors that lead to a large proportion of women with Turner syndrome developing hypertension through life .

- A **blunted nocturnal dipping** pattern in blood pressure (non-dipping) is common , which is present among hypertensive but also normotensive women with Turner syndrome.

- **Left ventricular mass** is statistically significantly increased even in normotensive patients with Turner syndrome compared with 46,XX women and **decreased myocardial glucose uptake** has also been observed, suggesting *myocardial insulin resistance* despite comparable whole-body insulin sensitivity.

- Such changes could be indicative of **early fibrotic changes** in the **LV** and be viewed as a forerunner for **diastolic dysfunction**.
- A strong association between **diastolic blood pressure** and **aortic dilation** has been found and suggests a window of opportunity to treat hypertension and thus prevent progressive aortic dilation over time.

- Women with Turner syndrome also exhibit a predominantly **proximal aortic stiffening**, which is observed at an **early age** and dilation, especially but *not exclusively, if their aortic valve is bicuspid.*
- The same changes are not observed in the ascending part of the aorta.



- The newest international guidelines on Turner syndrome recommend thorough cardiovascular evaluation of all women with Turner syndrome given the very high frequency of **congenital malformations**, a high frequency of **early onset hypertension** and an increased **cardiovascular morbidity and mortality**.

## Box 1 | Cardiac definitions relevant for Turner syndrome

### **Bicuspid aortic valves**

Normally, all individuals are born with a three-leaflet aortic valve. A bicuspid aortic valve occurs when two valves are fused into one as a consequence of an inherited form of heart disease and is seen in about 1–2% of the general population.

### **Aortic dilation**

Aortic dilation is present when the aortic diameter is greater than 1.5 times the normal diameter. It can be the forerunner of aortic dissection and is seen as a risk factor for this condition.

### **Sympathovagal tone**

The sympathetic and vagal (parasympathetic) nervous systems regulate heart rate and blood pressure in opposite directions, maintaining a normal sympathovagal tone. However, sympathovagal tone can be altered in different disease states, when either the sympathetic or the vagal activity, or both, are altered.

### **Coarctation of the aorta**

Aortic narrowing or coarctation of the aorta is a congenital condition of the aorta, usually seen where the ductus arteriosus inserts. It is associated with several congenital heart diseases.

### **Abnormal pulmonary venous drainage**

Normally, all four pulmonary veins connect to the left atrium. Abnormal pulmonary venous drainage is a congenital defect where the pulmonary veins drain to either the right atrium or the superior caval vein, creating left-to-right shunting of the saturated blood.

### **Subaortic obstruction**

Subaortic obstruction is a narrowing of the left ventricular outflow tract either due to a shelf-like structure under the aortic valve or due to a subaortic tunnel where the entire area of the heart from the base of the left ventricle to the aortic valve is narrowed.

### **Mitral valve dysplasia**

Mitral valve dysplasia is an overall term for all congenital mitral valve diseases. In Turner syndrome, the most common are parachute mitral valve diseases, where all chordae divide from one single papillary muscle. This can be seen together with supra-mitral stenosis, where a ring-like structure just above the mitral valve causes stenosis.

# Recommendation

- Clinical practice guidelines for the care of girls and women with Turner syndrome: proceedings from the 2016 Cincinnati International Turner Syndrome Meeting

- They recommend that an infant or child is examined with transthoracic echocardiography (TTE) at the time of diagnosis, even if the fetal echocardiogram or postnatal cardiac examination was normal.

- they recommend that girls or women with **aortic dilatation** and/or **bicuspid aortic valve** be counseled to seek prompt evaluation if they are experiencing acute symptoms, such as **chest, neck, shoulder, back or flank discomfort**, particularly if it is sudden in onset and severe.

- they recommend that women with TS demonstrating an increase in TS-specific Z-score of 1 in aortic diameter or an increase of >0.5 cm over a one-year period, need an optimization of medical treatment and surgical consultation.

- they suggest that elective operations for aneurysm of the aortic root and/or ascending aorta are reasonable for women with TS who are  $\geq 16$  years of age with an ascending ASI  $\geq 2.5$  cm/m<sup>2</sup> and associated risk factors for AoD, including bicuspid aortic valve, elongation of the transverse aorta, coarctation of the aorta and/or hypertension according to standard definitions.

- they suggest that elective operations for aneurysm of the aortic root and/or ascending aorta may be considered for women with TS who are  $\geq 16$  years of age with an ascending ASI  $\geq 2.5$  cm/m<sup>2</sup>, and no associated risk factors for AoD.



- they suggest that elective operations for aneurysm of the aortic root and/or ascending aorta may be considered for women with TS, who are <16 years of age, and for whom their ascending aorta TS-specific Z-score is  $\geq 4.0$ , with or without associated risk factors for AoD (i.e., bicuspid aortic valve, elongation of the transverse aorta, coarctation of the aorta and/or hypertension).

- They recommend that in adolescents and adults TS cardiovascular screening with TTE and CMR at the time of diagnosis is the preferred approach.

- they recommend that a CMR scan is performed as soon as it is feasible without needing general anesthesia. If an adult or child cannot tolerate a CMR study, a CT scan is a reasonable option.

- they recommend, in the absence of a bicuspid aortic valve or other significant disease at the initial screening, TTE or CMR surveillance studies should be performed every 5 years in children, every 10 years in adults, or prior to anticipated pregnancy to evaluate the aorta based on published guidelines.

- they recommend that, if TS is highly suspected or has been confirmed prenatally, a fetal echocardiogram should be performed.

- they recommend that diagnosis of a bicuspid aortic valve or a left-sided obstructive lesion in a female fetus or child should prompt a genetic evaluation for TS.

- they recommend referral to a pediatric cardiologist when congenital heart disease is detected prenatally in a fetus with TS to provide counseling regarding the anatomy and physiology of the specific defect, recommended site and mode of delivery and postnatal multidisciplinary management plan.

- they suggest that a resting electrocardiogram (ECG) with QTc measurement should be done in every individual with TS at the time of diagnosis and that Hodge's may be preferred over Bazett's formula to estimate QTc.



- they suggest that 24-h Holter monitoring and exercise testing be considered for risk estimation in women with TS with QTc interval prolongation (QTc >460 ms).

- they suggest that, in individuals with prolonged QTc, drugs that prolong the QTc should be avoided. If they are deemed necessary, ECG should be performed 1–2 weeks after initiation of QT-prolonging drugs.

- they recommend that the function of the aortic valve and the presence of any other congenital heart disease and/or hypertension should be considered in determining participation recommendations for the athlete with TS and aortic dilation.

- they suggest that, for girls and women with TS  $\geq 16$  years with a moderately dilated aorta (ascending ASI  $\geq 2.0$  cm/m<sup>2</sup>), avoidance of intense weight-training should be advised.

- they suggest that, for girls and women with normal aortic size (age <16 years; TS-specific Z-score of <2.5 or age  $\geq$ 16 years and ASI <2.0 cm/m<sup>2</sup>), it is reasonable to participate in all sports.

- they suggest that, for girls and women with a mild to moderately dilated aorta (age <16 years old (TS-specific Z-score of 2.5–3), or age ≥16 years (ASI 2.0–2.3 cm/m<sup>2</sup>)), participation in **low and moderate static and dynamic competitive sports may be advised.**

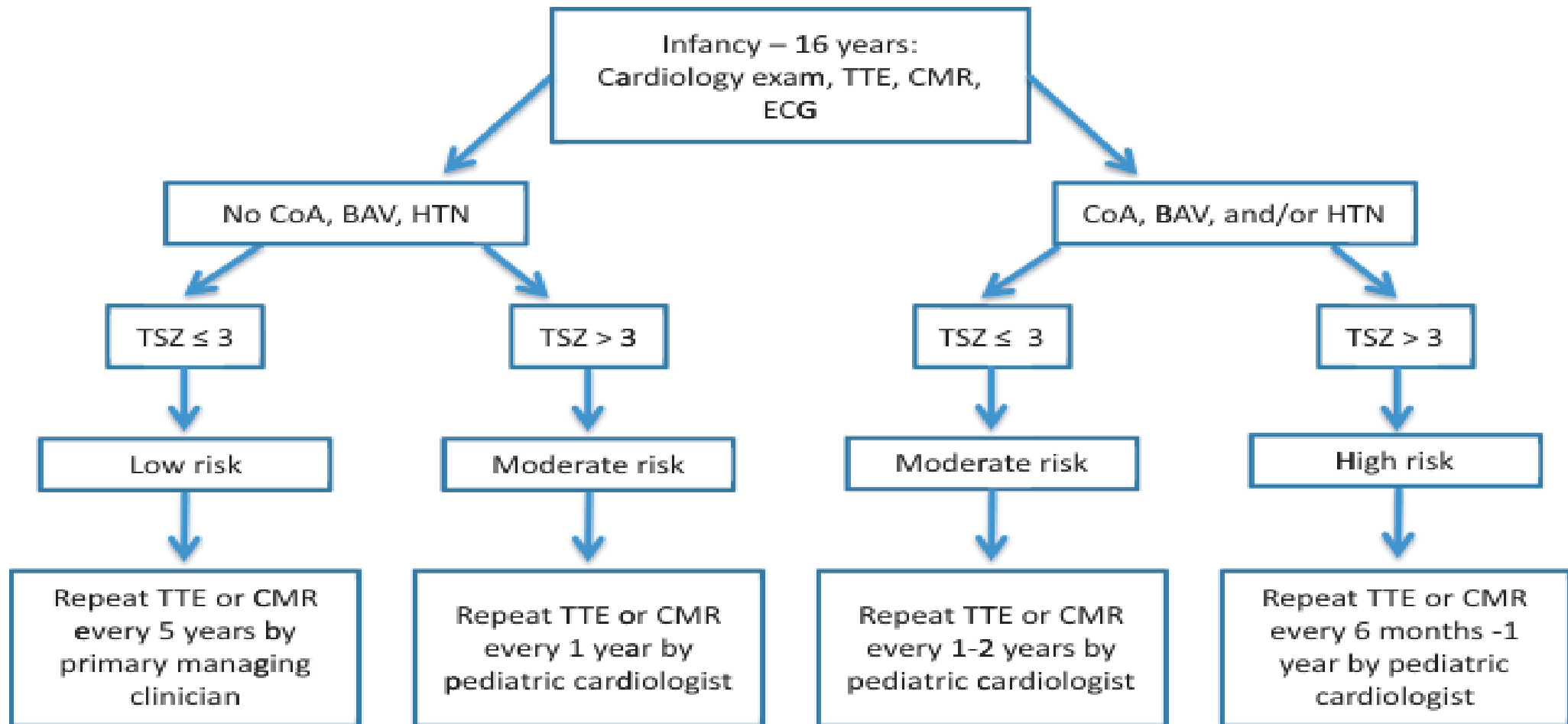
- they suggest that girls and women with a moderately to severely dilated aorta, age <16 years (TS-specific Z-score of >3) or age ≥16 years (ASI >2.3 cm/m<sup>2</sup>) should be advised not to participate in **any competitive sports**.

- they recommend that in individuals without structural heart disease, annual assessment of blood pressure should be performed and medical treatment there of should be considered if hypertension is present.



- They suggest medical treatment to include a beta-blocker, an angiotensin receptor blocker or both to reduce the risk for AoD in women with TS who are  $\geq 16$  years of age for whom their ascending ASI is  $\geq 2.3$  cm/m<sup>2</sup>.

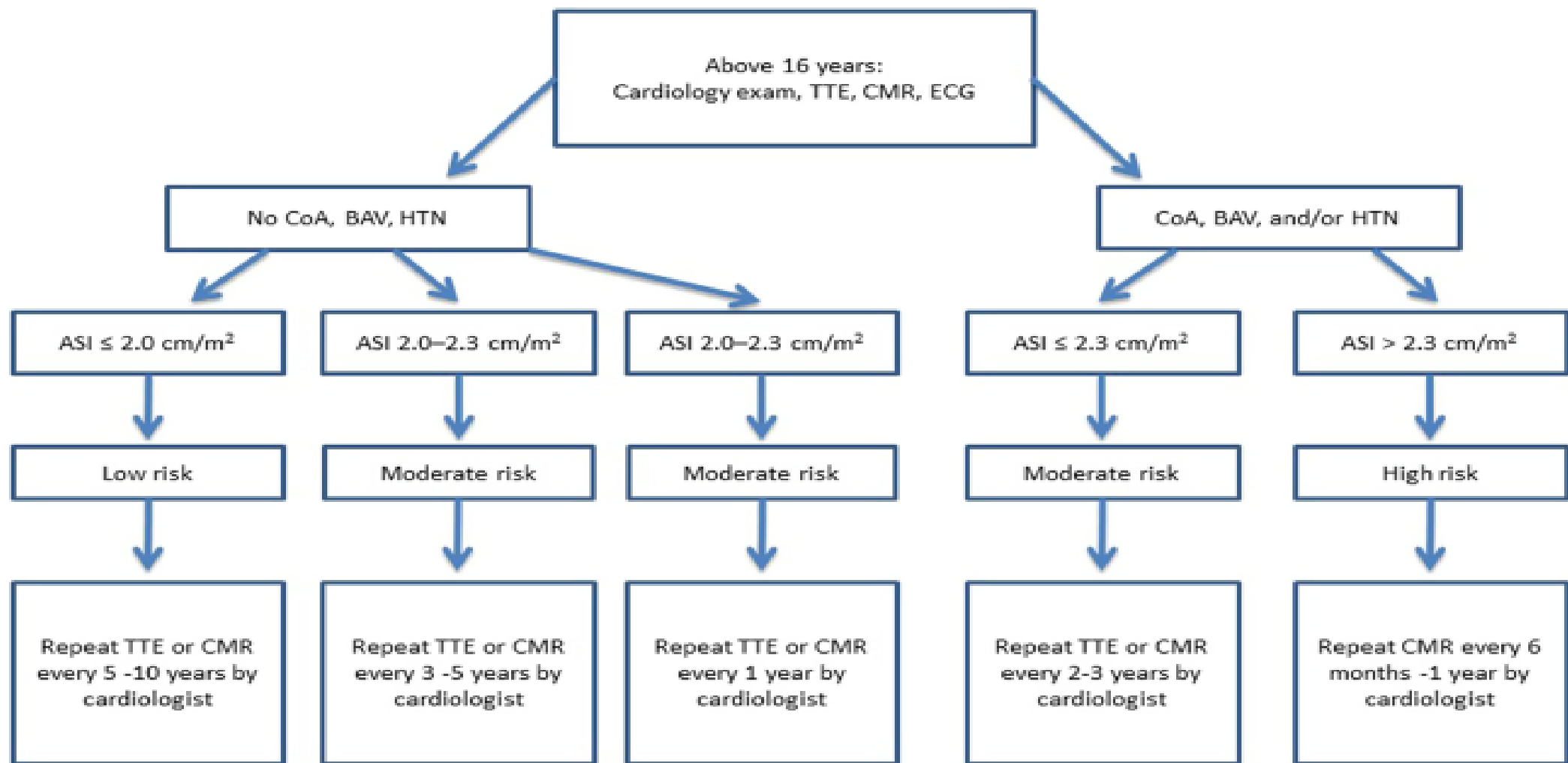
- they suggest that medical treatment, including a **beta-blocker**, an **angiotensin receptor blocker** or **both**, to reduce dilatation of an enlarged aortic root and/or ascending aorta may be considered for girls with TS who are  $\leq 16$  years of age for whom their ascending aorta TS-specific Z-score is  $\geq 3.0$ .



TTE: transthoracic echocardiography. CMR: cardiac magnetic resonance imaging. ECG: electrocardiogram. CoA: coarctation of aorta. BAV: bicuspid aortic valve. HTN: hypertension. TSZ: Turner syndrome specific Z-score of the aorta (see text for explanation).

**Figure 1**

Suggested monitoring protocol for girls with TS from infancy to 16 years of age. TTE, transthoracic echocardiography; CMR, cardiac magnetic resonance imaging; ECG, electrocardiogram; CoA, coarctation of aorta; BAV, bicuspid aortic valve; HTN, hypertension; TSZ, Turner syndrome specific Z-score of the aorta (see text for explanation).



**Figure 2**

Suggested cardiac monitoring protocol for girls and women with TS above 16 years of age. TTE, transthoracic echocardiography; CMR, cardiac magnetic resonance imaging; ECG, electrocardiogram; CoA, coarctation of aorta; BAV, bicuspid aortic valve; HTN, hypertension; ASI, aortic size index (see text for explanation).